

## ANEURYSM ASSOCIATED WITH FENESTRATION OF BASILAR ARTERY TREATED BY EMBOLIZATION WITH COILS

### *Aneurisma asociado a fenestración de la arteria Basilar tratado mediante embolización con coils*

ZINDYA G. BARRIENTOS M.<sup>1a</sup>, RODOLFO RODRIGUEZ V.<sup>1b</sup>, WALTER DURAND C.<sup>1b</sup>, RICARDO VALLEJOS T.<sup>1b</sup>, DANTE VALER G.<sup>1b</sup>, JESUS FLORES Q.<sup>1b</sup>

<sup>1</sup>Department of Neurosurgery, Section of Neuroradiology, Guillermo Almenara Irigoyen National Hospital, Lima, Perú, <sup>a</sup>Resident of Neurosurgery, <sup>b</sup>Neurosurgeon

#### ABSTRAC

**Introduction:** Aneurysms of the vertebrobasilar junction are rare, but when present, they are often associated with fenestration of the basilar artery. Frequently, the endovascular treatment is the first choice due to the complex anatomy of the posterior fossa.

**Clinical case:** A 68-year-old man from Lima, who denies important antecedents, was admitted to the emergency unit with intense holocranial headache, diplopia, posterior cervical pain and vomiting, without loss of consciousness. The neurological exam showed: score of 15 in the Glasgow coma scale (GCS), no pupillary alteration, no motor or sensitivity deficit, palsy of the left sixth cranial nerve and Hunt-Hess grade II. For decision making, the patient underwent digital subtraction angiography (DSA) through the right femoral artery with 3D reconstruction (03-08-2018) which showed evidence of fenestration of the basilar artery associated with saccular aneurysm. An aneurysm coil embolization was performed without complications. The patient was discharged maintaining diplopia, with paralysis of the left sixth cranial nerve, but without any other complaints or neurological symptoms.

**Conclusion:** Fenestrated basilar artery aneurysms are rare and complex vascular diseases and their treatment improved with the advent of the 3D angiography and the development of the endovascular techniques. The endovascular treatment by coil embolization is the first option although other endovascular techniques have also been described.

**Keywords:** Intracranial Aneurysm, Basilar Artery, Endovascular Procedures. (source: MeSH NLM)

#### RESUMEN

**Introducción:** Los aneurismas de la unión vertebrobasilar son raros, pero cuando están presentes, a menudo se asocian con la fenestración de la arteria basilar. Con frecuencia, el tratamiento endovascular es la primera elección debido a la compleja anatomía de la fosa posterior.

**Caso clínico:** paciente varón procedente de Lima de 68 años de edad, quien niega antecedentes importantes, ingresó a la unidad de emergencia con cefalea intensa holocraneana, diplopía, dolor cervical y vómitos, sin pérdida de conciencia. Al examen neurológico: puntuación de 15 en la escala de coma de Glasgow (GCS), sin alteración pupilar, sin déficit de sensibilidad motora, parálisis del sexto nervio craneal izquierdo y grado II de Hunt-Hess. Para la toma de decisiones, el paciente se sometió a una angiografía de sustracción digital (DSA) a través de la arteria femoral derecha con reconstrucción 3D que mostró fenestración de la arteria basilar asociada a un aneurisma sacular. Se realizó una embolización con coils del aneurisma sin complicaciones. El paciente fue dado de alta manteniendo la diplopía, con parálisis del sexto nervio craneal izquierdo, pero sin ningún otro síntoma neurológico.

**Conclusión:** Los aneurismas de la arteria basilar fenestrada son enfermedades vasculares complejas, y su tratamiento mejoró con el advenimiento de la angiografía 3D y el desarrollo de técnicas endovasculares. El tratamiento endovascular mediante embolización con coils es la primera opción, aunque otras técnicas endovasculares también han sido descritas.

**Palabras clave:** Aneurisma intracraneal, Arteria Basilar, Procedimientos Endovasculares. (fuente: DeCS Bireme)

Peru J Neurosurg 2019, 1(2): 43-46

**F**enestration of the basilar artery occurs in 0.6% to 2.3% of the angiograms and in 1-5% of the autopsies.<sup>1,2</sup> It can occur anywhere along the basilar artery, but is more common near the basilar artery. vertebrobasilar junction.<sup>3</sup>

**Submitted :** October 26, 2018

**Accepted :** February 22, 2019

**HOW TO CITE THIS ARTICLE:** Barrientos Z, Rodríguez R, Durand W, Vallejos R, Valer D, Flores-Q J. Aneurysm associated with fenestration of Basilar artery treated by embolization with coils. *Peru J Neurosurg* 2019; 1(2): 43-46

Saccular aneurysms of the vertebrobasilar junction are rare, but when present, they are often associated with fenestration of the basilar artery.<sup>4</sup>

Aneurysms of the vertebrobasilar junction usually appear in the proximal portion of the fenestration. The surgical treatment of these aneurysms is difficult due to the complex

geometry of the fenestration, the proximity of the lower cranial nerves, the presence of multiple small perforating arteries in the brainstem and the difficulties in obtaining adequate surgical exposure.<sup>5,6</sup> therefore, the endovascular treatment of such intracranial aneurysms is now widely accepted.<sup>2</sup>

We describe a case that began with subarachnoid hemorrhage (SAH) and was successfully treated by embolization with coils.

## CASE REPORT

**History and Examination:** 68-year-old male patient, born in Cajamarca and coming from Lima, who denies important antecedents, denies drug allergies. Patient admitted to the Emergency Service (30-07-2018) for presenting a sudden clinical picture, which began 6 hours before admission, characterized by intense holocranial headache, posterior cervical pain, diplopia and vomiting, without loss of consciousness.

The neurological examination: 15 points on the Glasgow coma scale, no pupillary alteration, absence of motor or sensitivity deficit, paralysis of the sixth left cranial nerve, Hunt-Hess grade II; in the computed tomography, subarachnoid hemorrhage (SHA) Fisher grade III was evident (► Fig.1). For decision making, the patient underwent a digital subtraction angiography (DSA) through the right femoral artery with 3D reconstruction (03-08-2018) that showed fenestration of the basilar artery in its proximal third, associated with saccular aneurysm. (► Fig.2)

**Endovascular treatment:** Embolization of the aneurysm (07-08-2018) with general anesthesia 6F introducer was inserted into right femoral artery under Seldinger technique, with H1 diagnostic catheter of 5F angiographic study of left

vertebral artery was performed, in the different incidences and in the 3D reconstruction, it was possible to demonstrate the presence of a proximal third aneurysm of the fenestrated basilar artery.

The left vertebral artery was approached with Envoy® guide catheter of 6F, guided with Excelsior® microcatheter and assisted with Traxcess-14® microguide reaching the dome of the aneurysm (► Fig.3). It was decided to embolize with 4mm x 12mm coils. During the placement of the first coil, this migrated through the wide neck, so it was decided to place an Envoy® catheter at the level of the right vertebral artery and the Remodeling balloon technique was performed, for this purpose Transform® ball was used assisted by microguide Traxcess- 14® which was placed in the final segment of the vertebral artery and proximal of the basilar artery, thus covering the neck of the aneurysm. It was possible to embolize with coils without problems (► Fig. 4).

**Evolution:** The patient evolved favorably on postoperative. The patient was discharged 13 days later, maintaining diplopia and paralysis of the sixth left cranial nerve, without motor deficit, without sensory deficit.

## DISCUSSION

A fenestration is defined as a single artery with two luminal channels that may or may not share its adventitious layer.<sup>6</sup> The basilar artery is the second most common site of intracranial fenestration, after the anterior communicating artery<sup>3,7</sup> and it is an infrequent anatomical variant caused by a failure in the fusion of paired longitudinal nerve arteries during fetal life.<sup>1</sup> The failure of this process of fusion

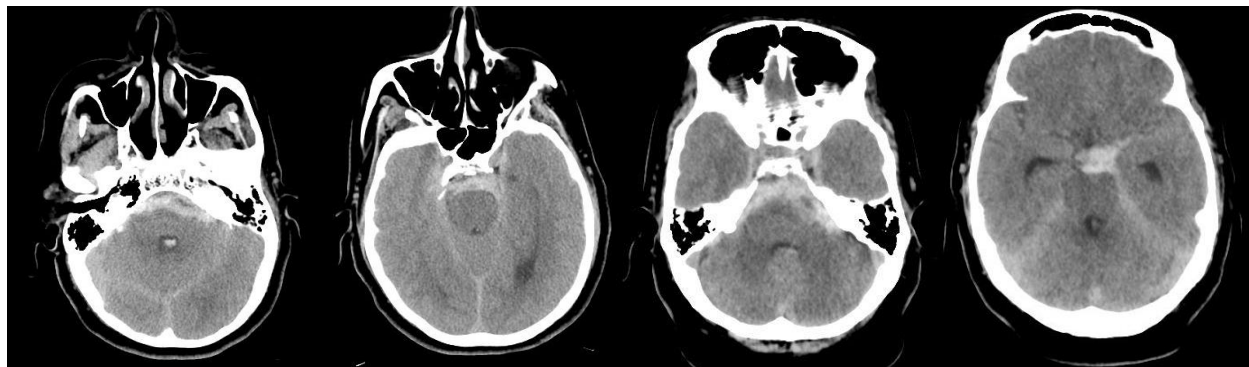
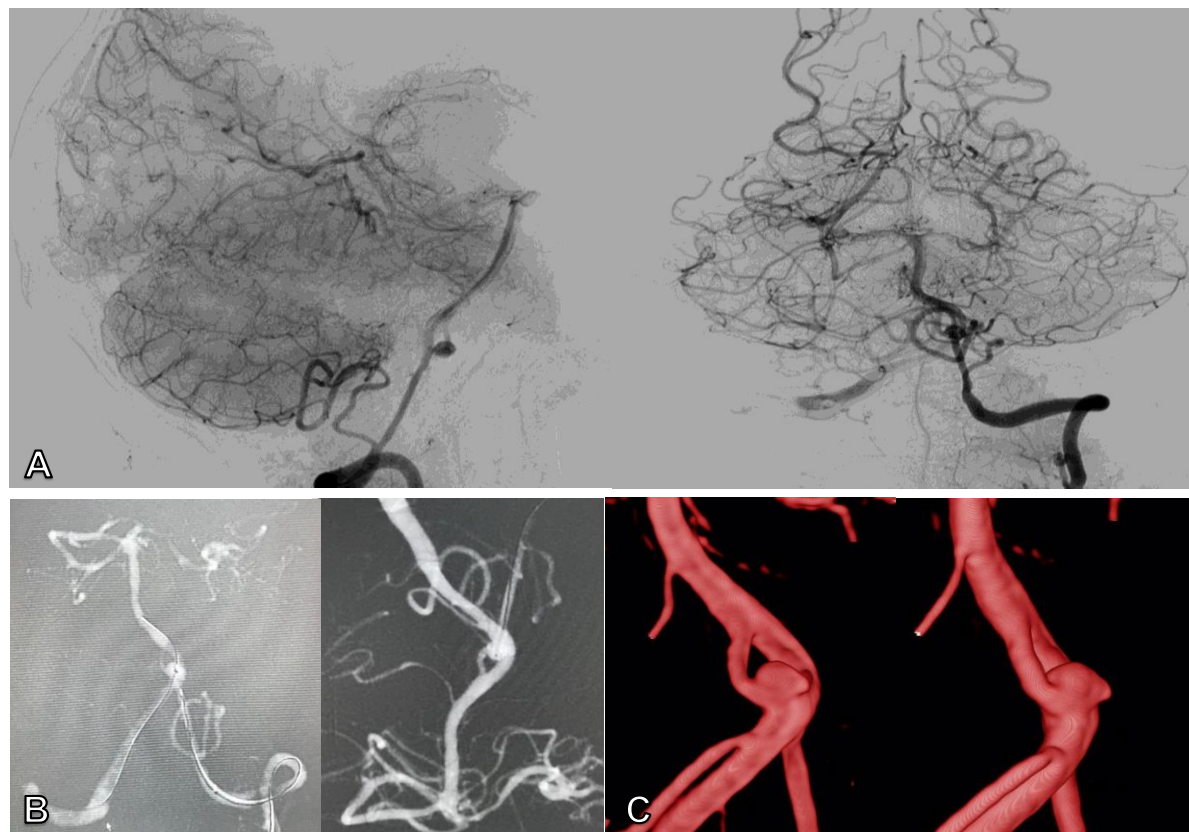


Fig.1. Brain computed tomography without contrast showing a subarachnoid hemorrhage involving basal cisterns (Fisher III SHA)

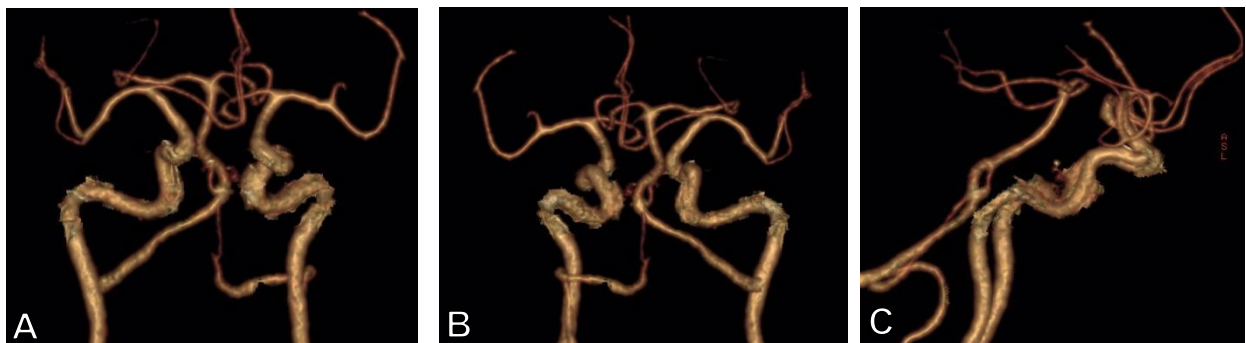

Fig. 2. Anterior (A), posterior (B) and lateral (C) view of three-dimensional (3D) angiography confirms a ruptured aneurysm in the fenestration loop of the basilar artery in its proximal third (4.35 x 1, 97 x 4.36 mm)



**Fig. 3.** (A and B) Right and left vertebral artery angiography. (B) View of roadmapping during the endovascular procedure shows the Excelsior® microcatheter in the basilar artery. (C) 3D reconstruction of aneurysm.

with a persistent bridge artery can lead to a fenestration anywhere along the course of the basilar artery but more frequently in the proximal portion<sup>8</sup>.

The basilar artery fenestration can be classified into two types according to Kai et al. He proposed two types of classification. Type A has a bridge artery between the distal V4 portions of both vertebral arteries. Type B does not have a bridge artery and a somewhat elliptical fenestration<sup>9</sup>. The association between the fenestration of the Basilar artery and aneurysms is reported between 25 and 50% of cases<sup>8</sup>. Most tend to debut with SHA<sup>9</sup>. These aneurysms are complex because of their location and their morphology, so surgical treatment is usually laborious due to the complicated geometry of the fenestration and difficulties in obtaining adequate surgical exposure<sup>10</sup>.

With the improvement of 3-dimensional angiographic technology and endovascular technique, Trivelato et al. proposed a new classification based on the size of the neck of the aneurysm and the base of implantation in the proximal bifurcation of the fenestration. Four types are the same as the following: 1A: narrow neck, symmetrical at the bifurcation. 1B: narrow neck, jump a loop. 2A: wide neck, involves both loops. 2B: wide neck, spare a loop<sup>2</sup>.

Modern advances in endovascular surgery for aneurysms have replaced a large part of aneurysm clipping surgery<sup>8</sup>. Endovascular therapy has proven to be an effective and safe method in the management of intracranial aneurysms<sup>11</sup>. Aneurysms originating in the vertebrobasilar junction require an approach to the base of the skull and a critical dissection around the brain stem. In addition, the cutting of

large aneurysms associated with fenestration of the proximal basilar artery is very difficult, and endovascular coiling is the main treatment option in this type of aneurysm.<sup>12</sup>

It has been reported in case series that endovascular treatment was successful without causing new neurological deficits<sup>1</sup>, even one limb in the fenestration was intentionally occluded during the endovascular procedure and no neurological sequelae were developed.<sup>13</sup>

In our patient the neck of the aneurysm was wide, so the balloon was used to support the winding of the aneurysmal sac with flow preserved proximally, distally, the patient withdrew without incapacitating neurological deficit.

## CONCLUSION

The aneurysms associated with fenestration of the basilar artery are complex and infrequent vascular lesions. Endovascular treatment is reported be the first option due to the intricate anatomy of the posterior fossa. Taking into account the lower degree of invasiveness and the satisfactory results of the treatment, coil embolization can represent a superior treatment option to address difficult aneurysms with a complicated anatomy due to the presence of arterial fenestration<sup>14</sup>.

Recent advances in techniques and instrumentation for endovascular treatment will continue to make embolization the safest and most efficient surgical technique.



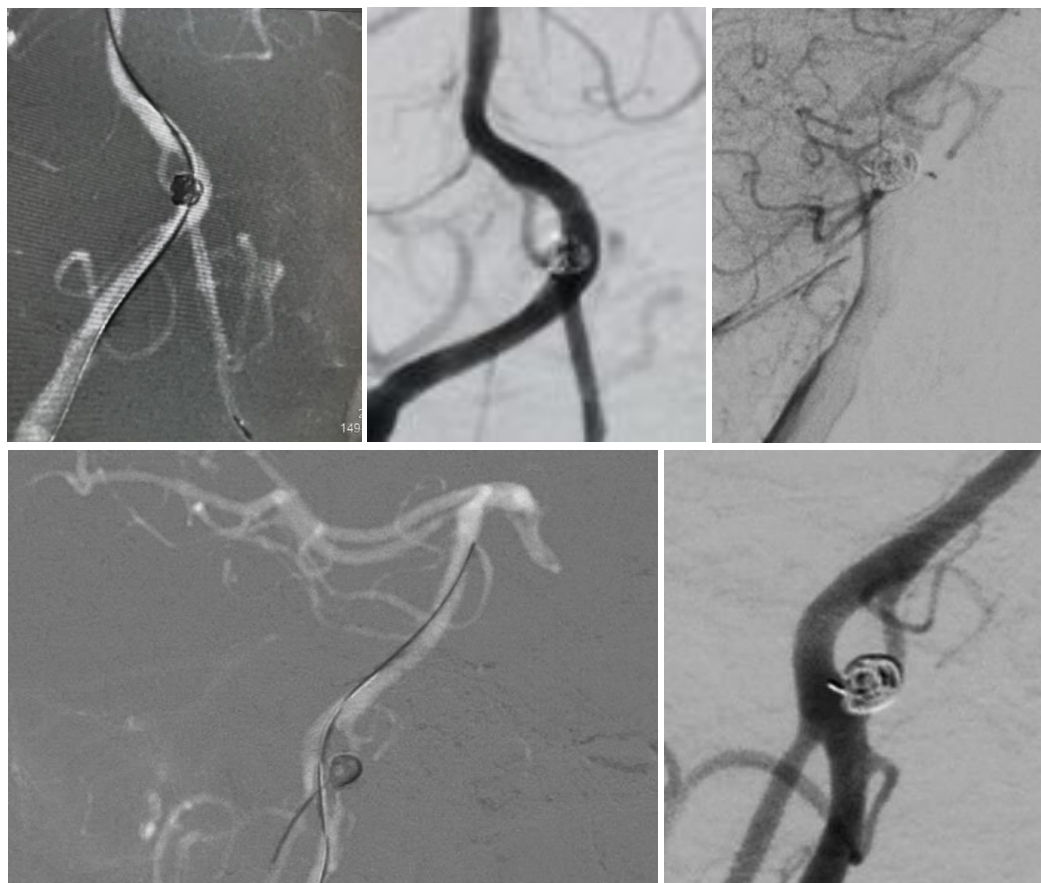


Fig. 4. Angiography shows complete embolization of the aneurysm with excellent permeability of the posterior circulation.

## REFERENCES

1. Tanaka S, Tokimura H, Makiuchi T, et al. Clinical presentation and treatment of aneurysms associated with basilar artery fenestration. *J Clin Neurosci* **2012**;19(03):394-401
2. Trivelato FP, Abud DG, Nakiri GS, et al. Basilar artery fenestration aneurysms: endovascular treatment strategies based on 3D morphology. *Clin Neuroradiol* **2016**;26(01):73-79
3. Curado VL, Andre TD, Crociati ML, et al. Aneurysms of the Fenestrated Basilar Artery: Case Report and Literature Review. *Arq Bras Neurocir* **2017**; **36**:225-229.
4. Valsechi, L., Meguins, L., Maia, I., Fares, A., Taffarel, D., & Hidalgo, R. Aneurysm of the Fenestrated Basilar Artery: Case Report and Literature Review. *Arquivos Brasileiros de Neurocirurgia: Brazilian Neurosurgery*. **2017**; **36**(04), 225-229.
5. Graves VB, Strother CM, Weir B, Duff TA: Vertebrobasilar junction aneurysms associated with fenestration: treatment with Guglielmi detachable coils. *AJNR Am J Neuroradiol* **17**: 35-40, 19966.
6. Gao LY, Guo X, Zhou JJ, et al. Basilar artery fenestration detected with CT angiography. *Eur Radiol*. **2013**;23(10):2861-7.
7. Dodevski A, Lazareska, Tosovska-Lazarova D, Zhivadinovik J, Sto-jkoski A. Basilar artery fenestration. *Folia Morphol (Warsz)*. **2011**; **70**(2):80-3.
8. Park, W. B., Sung, J. H., Huh, J., Cho, C. B., Yang, S. H., Kim, I. S., Double Stent Assist Coiling of Ruptured Large Saccular Aneurysm in Proximal Basilar Artery Fenestration. *Journal of Cerebrovascular and Endovascular Neurosurgery*. **2015**; **17**(3), 227-233.
9. Kai, Y., Hamada, J., Morioka, M., Yano, S., Fujioka, S., & Kuratsu, J. Endovascular treatment of ruptured aneurysms associated with fenestrated basilar artery. Two case reports. *Neurología Medico-Chirúrgica*. **2006**, **46**(5), 244-247.
10. Foroni LHL, Figueiredo EG, Teixeira JM, Caldas JGMP, Leszczynski A, Rivau FR. Saccular aneurysms at middle basilar trunk fenestration. *Arq Neuropsiquiatr*. **2010**;68(2):309-11.
11. Franco, J. S., Vázquez, L. Á., Andrade, R. S., & Balanzario, M. A. S. (2014). Tratamiento endovascular de aneurisma asociado a fenestración de la arteria basilar. Reporte de un caso. *Gaceta Médica de Mexico*.
12. Yoon SM, Chun YI, Kwon Y, Kwun BD. Vertebrobasilar junction aneurysms associated with fenestration: experience of five cases treated with Guglielmi detachable coils. *Surg Neurol*. **2004 Mar**;61(3):248-54.
13. Albanese E, Russo A, Ulm AJ. Fenestrated vertebrobasilar junction aneurysm:diagnostic and therapeutic considerations. *J Neurosurg* **2009**; **110**:52

### Disclosures

The authors report no conflict of interest concerning the materials or methods used in this study or the findings specified in this paper.

### Author Contributions

*Conception and design:* All the authors. *Drafting the article:* Barrientos. *Critically revising the article:* Rodriguez R. *Reviewed submitted version of manuscript:* Barrientos. *Approved the final version of the manuscript on behalf of all authors:* Barrientos.

### Correspondence

Zindy Barrientos Mávila. Department of Neurosurgery. Guillermo Almenara Irigoyen Hospital. 800 Grau Avenue. La Victoria. Lima 13, Perú. E-mail: [zindyabm@icloud.com](mailto:zindyabm@icloud.com)