

CHOROID PLEXUS COAGULATION AS AN ISOLATED PROCEDURE IN THE TREATMENT OF HYDROCEPHALUS

Coagulación de plexo coroideo como procedimiento aislado en el tratamiento de la hidrocefalia

STEFANO SMOQUINA, S.¹, JOSÉ MANUEL ZULUETA.²

¹Neurosurgery, University of Valparaíso, Chile

^a Neurosurgery Fellow. ^b Student of the VII year of Medicine

ABSTRACT

Objectives: The objective of this review is to determine the effectiveness of isolated choroid plexus coagulation (CPC) as a treatment for hydrocephalus in various clinical settings and the variables associated with its success.

Methods: PubMed was searched for the terms (choroid plexus coagulation) OR (choroid plexus cauterization). Those studies published since 1990 were included so that they were relevant to current clinical practice. All studies evaluating the efficacy of CPC as an isolated procedure for treating hydrocephalus were included.

Results: The etiology, approach, and degree of CPC were significantly associated with the effectiveness of the procedure. The greatest effectiveness was reported in patients with hydranencephaly or maximum hydrocephalus (68.9%, $p = 0.001276$), when a parietal approach was used (74.4%, $p = 0.000604$), and when the temporal horn plexus was included (64.7%, $p = 0.048068$). Furthermore, a case of choroid plexus hyperplasia (CPH) treated effectively with CPC is described. On the other hand, the type of electrode ($p = 0.4631$), the type of endoscope ($p = 0.0699$), and the presence of a previous ventriculoperitoneal shunt ($p = 0.3241$) were not significantly associated with the effectiveness of CPC.

Conclusions: CPC is a viable treatment alternative in the management of hydranencephaly, CPH, and in selected cases of hydrocephalus without the aforementioned characteristics. However, studies are needed to compare CPC with shunt therapies before qualifying it as the first line of treatment.

Keywords: Choroid Plexus, Cautery, Hydrocephalus, Hydranencephaly, Ventriculoperitoneal Shunt. (source: MeSH NLM)

RESUMEN

Objetivos: El objetivo de esta revisión es determinar la efectividad de la coagulación de plexo coroideo (CPC) aislada como tratamiento para la hidrocefalia en diversos escenarios clínicos y las variables asociadas a su éxito.

Métodos: Se hizo la búsqueda en PubMed de los términos (choroid plexus coagulation) or (choroid plexus cauterization). Se incluyeron aquellos estudios publicados desde 1990, de manera que fueran relevantes para la práctica clínica actual. Se incluyeron todos aquellos estudios en que se evaluó la eficacia de la CPC como procedimiento aislado para tratar la hidrocefalia.

Resultados: La etiología, el abordaje y el grado de CPC se asociaron significativamente a la efectividad del procedimiento. La mayor efectividad se reportó en pacientes con hidranencefalia o hidrocefalia máxima (68.9%, $p = 0.001276$), cuando se usó un abordaje parietal (74.4%, $p = 0.000604$), y cuando se incluyó el plexo de los cuernos temporales (64.7%, $p = 0.048068$). Además, se describe un caso de hiperplasia de plexo coroideo (HPC) tratada eficazmente con CPC. Por otro lado, el tipo de electrodo ($p = 0.4631$), el tipo de endoscopio ($p = 0.0699$) y la presencia de una derivación ventriculoperitoneal previa ($p = 0.3241$) no se asociaron significativamente con la efectividad de la CPC.

Conclusiones: la CPC es una alternativa de tratamiento viable en el manejo de hidranencefalia, HPC y en casos seleccionados de hidrocefalia sin las características antes mencionadas. Sin embargo, se hacen necesarios estudios que comparen CPC con terapias de derivación antes de calificarla como una primera línea de tratamiento.

Palabras Claves: Plexo Coroideo, Cauterización, Hidrocefalia, Hidranencefalia, Derivación Ventriculoperitoneal (fuente: DeCS Bireme)

Peru J Neurosurg 2021, 3 (2): 51-60

Submitted : January 28, 2021

Accepted : March 30, 2021

HOW TO CITE THIS ARTICLE: Smoquina S, Zulueta J-M. Choroid plexus coagulation as an isolated procedure in the treatment of hydrocephalus. *Peru J Neurosurg* 2021; 3 (2): 51-60

Choroid plexus coagulation (CPC) is a procedure that arises from the historical attempt to treat hydrocephalus,¹⁻⁷ however, it is replaced by bypass therapies as the standard of treatment due to better results.⁸ Complications of CSF shunts can be serious, so any method of reducing dependence on these can be beneficial for patients, especially in social and health contexts with difficult access to care and a health system with significant financial limitations. Up to 14% failure of CSF shunts is reported per month and 20 to 50% in the first year in the general population with hydrocephalus.⁹

Currently, the main use of CPC as a primary procedure for the treatment of hydrocephalus is in combination with endoscopic third ventriculostomy (CPC / ETV). This procedure gained popularity mainly due to studies published in Sub-Saharan Africa by Warf, in an attempt to reduce the number of ventricular shunts due to the difficulty of access to healthcare in that area and the associated complications.¹⁰⁻¹⁷

However, CPC also has its place as a treatment for hydrocephalus as an isolated procedure. The cases with the greatest benefit from a CPC alone correspond to cases in which the placement of a CSF shunt may have higher risks, such as hydranencephaly and maximal hydrocephalus.¹⁸ These risks include leakage of CSF due to a minimal or absent cerebral cortex, dysfunction of the shunt, over drainage, infection, and breakdown of the skin at the insertion site.^{19,20}

Likewise, CPC takes place in the management of choroid plexus hyperplasia (CPH), a rare pediatric disorder, with few cases reported in the literature, in which CSF overproduction would always be present.²¹ The installation of a shunt of CSF alone in these patients is at high risk of complication and does not constitute an etiological treatment.²¹ Part of the definitive treatment that has been offered to most of these patients is microsurgical plexectomy, which presents a high risk of bleeding.²²

These risks are what have led researchers and clinicians to seek a viable treatment alternative for these cases of hydrocephalus. The objective of this review is to determine the effectiveness of isolated CPC as a treatment for hydrocephalus in various clinical settings and the variables associated with its success.

METHODS

PubMed was searched for the terms (*choroid plexus coagulation*) OR (*choroid plexus cauterization*). Those studies published since 1990 were included so that they were relevant to current clinical practice. All studies

evaluating the efficacy of CPC as an isolated procedure for treating hydrocephalus were included.

A detailed review of the references of the selected papers provided additional studies. Historical reviews about the procedure and exclusive review articles were excluded.

All patients in whom CPC was associated with another concomitant procedure, or whose aim was not to evaluate it as a therapy for hydrocephalus, were excluded from the results. Results corresponding to the same patient in different studies were excluded from the statistical analysis.

A total of 329 results were found, of which 12 were included in the data processing of the results of the review.

The chi² test was used to determine the association between variables and the outcome in a population with an assumed normal distribution and Fisher's exact test when associating a population in which normality of the sample distribution could not be assumed.

RESULTS

The total N evaluated in this review was 210 patients, with an overall success of CPC as a treatment for hydrocephalus of 46.7%. It was defined as the success of the procedure that the patients did not need another intervention to control hydrocephalus at the end of the follow-up. The data from the primary studies are summarized in *Table 1*.

The studies do not provide sufficient information on sex, head circumference (CC), rate of CC progression, or age at the time of surgery to determine an association with the effectiveness of the treatment. *Table 2* shows the effectiveness according to available variables.

The etiology, approach, and degree of CPC were associated with the effectiveness of the procedure. The greatest effectiveness was reported in patients with hydranencephaly or maximum hydrocephalus (almost hydranencephaly, little cortical remnant) (68.9%, $p = 0.001276$), when a parietal approach was used (74.4%, $p = 0.000604$), and when the plexus was included of the temporal horns (64.7%, $p = 0.048068$). In extreme hydrocephalus (very thin cerebral cortex present, any etiology) the effectiveness was 37.5%. Ogiwara et al.⁴¹ reported hydranencephaly as an etiology in 1 patient but did not specify whether the procedure was successful or not, so it was not included in the effectiveness analysis when comparing etiology.

On the other hand, the type of electrode ($p = 0.4631$), the type of endoscope ($p = 0.0699$), and the presence of a previous ventriculoperitoneal shunt (VPS) ($p = 0.3241$) were not significantly associated with the effectiveness of CPC.

Tabla 1: Summary of various studies on Choroid Plexus Coagulation (CPC)

	Poppe y Elites ³⁸	Griffith y Jamjoom ³⁹	Morota y Fujiyama ⁴⁰	Okano et al. ⁴⁰	Ogijara et al. ⁴¹	Pedrosa et al. ⁴²	Shitsama et al. ⁴³	Sandberg et al. ⁴⁴	Gomes et al. ⁴⁵	Kim et al. ⁴⁶	Ray et al. ⁴⁷	Hallaert et al. ²¹	Resumen de datos
Edad promedio (rango)	NE (7 días - 30 años)	NE (NE)	2 meses	NE (<2 años)	NE (<2 años)	Éxito 4 meses Fracaso 17 meses (<2 años)	NE (<3 años)	Éxito 2 meses Fracaso 0.2 meses (2 días - 2 meses)	Éxito 3 meses Fracaso 48 meses (2 meses - 8 años)	2 semanas.	0.0 meses	36 meses	Éxito 4.6 meses (2 días - 3 años) Fracaso 8.6 meses (2 días - 8 años) NE (7 días - 30 años): 80.8%
Tiempo medio de seguimiento (rango)	10.5 años (<10.5 años - >16 años)	2.3 años (1 semana - 4 años)	1 año	NE (>36 meses)	NE (>17 meses)	NE (3 meses)	NE (1 - 50.7 meses)	NE (>2.5 meses)	1.7 meses (21 días - 90 días)	6 meses	1 mes	36 meses	8.6 años (3 semanas - >16 años) NE (1 mes - >4.2 años): 40.5%
Tiempo medio al fracaso (rango)	NE (<16 años)	2.5 meses (1 semana - 1 año)	No aplica	NE (<6 meses)	NE (<6 meses)	NE (<2 meses)	NE (8 - 608 días)	1 mes (1 mes)	2.2 meses (1.5 - 3 meses)	No aplica	No aplica	No aplica	2.5 meses (1 semana - 1 año) NE (8 días - 16 años): 85.7%
Tiempo operatorio medio	45 minutos.	40 minutos.	NE	NE	NE	47 minutos: 30% NE: 70%	NE	NE	NE	NE	NE	210 minutos. NE: 34.8%	45.5 minutos NE: 34.8%
DVP previa	No: 90 Si: 14	No	No	No	No	No	No	No	Si	No	No	Si	No: 91.4% Si: 8.6%
Electrodo	Monopolar	Monopolar	Monopolar	Monopolar	Monopolar	Monopolar	Monopolar	NE	Monopolar	Mono y bipolar	NE	Bipolar	Monopolar: 96.2% Mono y bipolar: 0.5% Bipolar: 0.5% NE: 2.9%
Endoscopio	Rígido	Rígido	Flexible	Flexible	Flexible	Rígido	Rígido	Rígido	Rígido	Rígido	NE	Rígido	Rígido: 93.8% Flexible: 5.7% NE: 0.5%
Etiología	Comunicante: 34 No comunicante: 18 Mielomeningocele: 30 Idiopática: 10 NE: 12	Mielomeningocele: 5 Posthemorrágica: 12 Congénita comunicante: 5 Postirriteciosa: 1	Posthemorrágica	Posthemorrágica: 2 Postirriteciosa: 1 Idiopática: 2	Posthemorrágica: 2 Postirriteciosa: 1 Hidranencefalia: 1 Idiopática: 1 Porencefalia: 1	Hidranencefalia: 22 Hidrocefalia máxima: 8	Hidranencefalia: 10 Postirriteciosa 0 Congénita extrema: 20	Hidranencefalia: 2 NE extrema: 3	Hidranencefalia: 1 Hidroencefalia: 1 Congénita extrema: 1	Hidranencefalia	Hidranencefalia	Hidranencefalia HPC	Hidranencefalia + hidrocefalia máxima: 21.9% Otros: 71.0% NE: 7.1%
Abordaje	Bi-occipital	Bi-occipital	Parietal	Parietal	Parietal	Parietal	Fontanela anterior	Frontoparietal	Frontoparietal	Parietal	NE	Bi-occipital	Bi-occipital 61% Parietal 20.5% Fontanela anterior 14.3% Frontoparietal 3.8% NE: 1: 0.5%
Grado de CPC	NE	Incluyó cuernos temporales	Incluyó cuernos temporales	Incluyó cuernos temporales	Incluyó cuernos temporales	Incluyó cuernos temporales	No incluyó cuernos temporales	NE	Incluyó cuernos temporales	NE	NE	NE	Incluyó cuernos temporales: 32.4% No incluyó cuernos temporales: 14.3% NE: 53.3%
Complicaciones	Meningitis: 4.8% Desplazamientos de drenaje: 3.8% Bloqueo o fuga de catéter ventricular: 3.8% Infecciones de dispositivos: 2.9% Convulsiones postoperatorias: 1.9% Sangrado intraoperatorio severo: 1.9% Etiología subaral: 1%	Meningitis 21.7%	NE	Sin complicaciones	Sin complicaciones	Sin complicaciones: 30% NE: 70%	Fuga de LCR: 10%	Sin complicaciones	NE	NE	Colapso aracnoideo	Colección subaral Infección de dispositivo	Meningitis: 5.4% Desplazamientos de drenaje: 2.2% Bloqueo o fuga de catéter ventricular: 2.2% Infecciones de dispositivos: 2.2% Convulsiones postoperatorias: 1.1% Sangrado intraoperatorio severo: 1.1% Colección subaral: 0.5% Etiología subaral: 0.5% Colapso aracnoideo: 0.5% NE: 12.4%
Efectividad global	36/104 (34.6%)	12/23 (52%)	1/1 (100%)	4/5 (80%)	4/6 (66.7%)	22/30 (73.3%)	13/20 (43.3%)	2/5 (40%)	1/3 (33.3%)	1/1 (100%)	1/1 (100%)	1/1 (100%)	98/210 (46.7%)

Tabla 2: Effectiveness of Choroid Plexus Coagulation (CPC) according to different variables

Abordaje	Bi-occipital: 49/128 (38.3%)	Parietal: 32/43 (74.4%)	Fontanela anterior: 13/30 (43.3%)	Frontoparietal: 3/8 (37.5%)		p = 0.0006
Grado de CPC	Incluyó cuernos temporales: 44/68 (64.7%)	No incluyó cuernos temporales: 13/30 (43.3%)				p = 0.0480
Etiología	Hidranencefalia + hidrocefalia máxima: 31/45 (68.9%)	Comunicante: 27/57 (47.4%)	Mielomeningocele 16/35	Idiopática 5/12	No comunicante 2/18 (11.1%)	p = 0.0012
DVP previa	No: 92/192 (47.9%)	Si: 6/18 (33.3%)				p = 0.3241
Electrodo	Monopolar: 93/202 (46.0%)	Bipolar 1/1: (100%)				p = 0.4631
Endoscopio	Rígido: 88/197 (44.7%)	Flexible: 9/12 (75%)				p = 0.0699

DISCUSSION

Hydrocephalus is a pathology with a reported mortality of up to 80% without treatment,⁴⁹ therefore, in medical practice, the implementation of effective therapies is essential. CPC reappears as an alternative treatment for hydrocephalus due to the inherent risks of a ventriculoperitoneal shunt (VPS).⁹ The main use of the CPC at present is together with the ETV to increase the effectiveness of the latter.¹⁰⁻¹⁷ However, the CPC also has a role as an isolated procedure.

The mechanism by which hydrocephalus develops is not fully elucidated, but the most widely accepted is that it would be generated by an imbalance between CSF production and absorption.²³ The traditional model of CSF net flow is based on CSF production in the choroid plexus, its subsequent distribution through the subarachnoid space, and finally its absorption in the arachnoid villi.

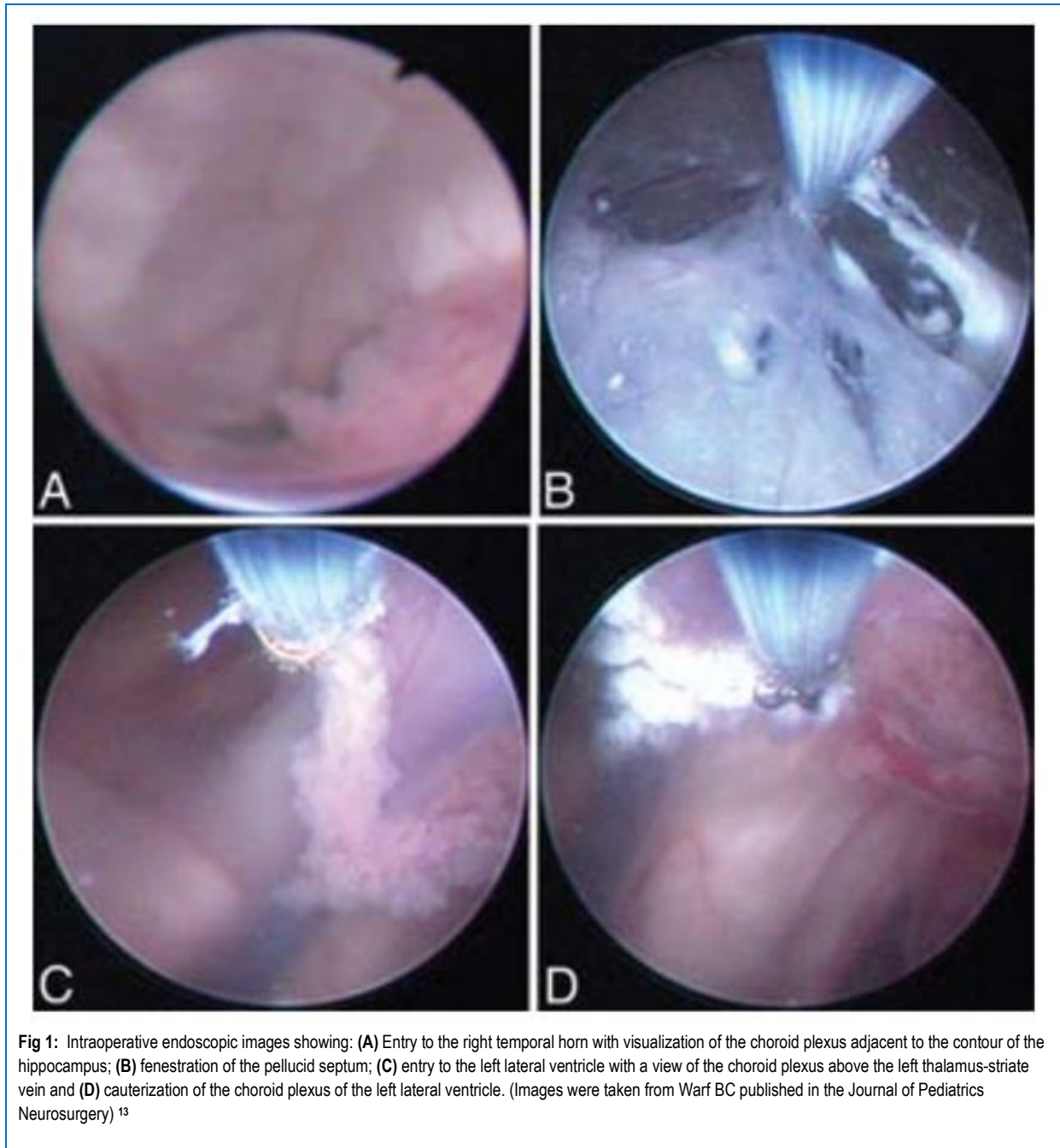
The presence of the choroid plexus has been reported as necessary for the production of ventriculomegaly.²⁴⁻²⁶ Other studies have shown that in a communicating hydrocephalus model the ventricles fail to expand in the absence of normal pulsatility of the choroid plexus.²⁷ Furthermore, the role of increased secretion of CSF by the choroid plexus in the development of hydrocephalus is reported.²⁸ Hypotheses suggest a decreased absorption of CSF in children, in part due to immature arachnoid villi more sensitive to changes in intracranial pressure (ICP), with a large decrease in resorption compared to slight increases in ICP.²⁹⁻³² The latter, associated with a skull with greater compliance, may mask the severity of the condition.³³ These studies represent, in part, the theoretical basis for CPC as a treatment for hydrocephalus.

In response to this model, a theory arises that tries to explain scenarios that the classical model cannot fully respond to, such as hydrocephalus without intracranial hypertension (ICP), arrested hydrocephalus, hydrocephalus

without a transepithelial pressure gradient, and CSF circuit obstruction without hydrocephalus. The new hydrodynamic model proposes that the interstitial fluid (IF) and the CSF volume (water) constitute a functional unit and are regulated by changes in the hydrostatic and osmotic pressures of microvessels throughout the entire central nervous system (CNS). The continuous turnover of the IF – CSF (water) volume would be created by the filtration of water through the walls of the arterial capillaries at high hydrostatic pressure with plasma retention of osmolytes (reflection coefficient of the main electrolytes Na⁺ and Cl⁻ is 0.98) and the reabsorption of water from the interstitium into the venous capillaries and postcapillary venules by the resulting osmotic backpressure. The changes in CSF volume would depend on physiological and pathophysiological processes that cause differences in osmolarity between the CNS compartments.³⁴

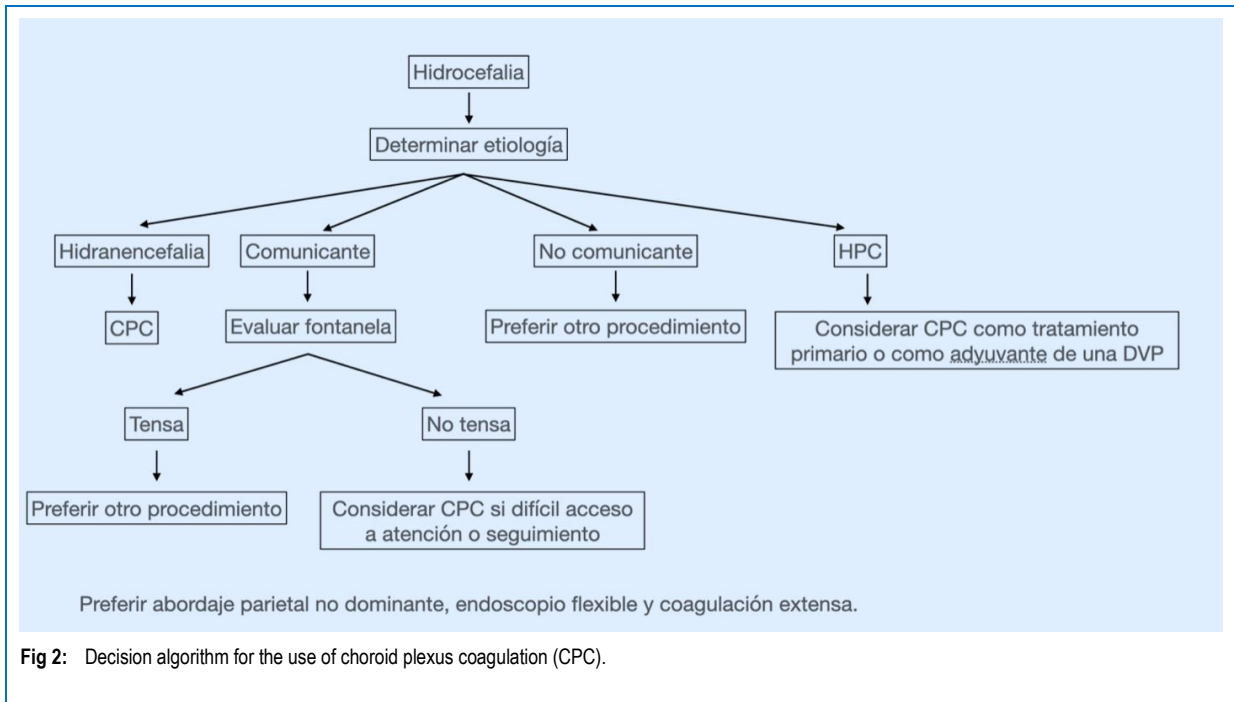
This theory is supported by the development of cerebral edema under conditions of decreased blood osmolarity in relation to the brain parenchyma and the CSF.^{35, 36} Conversely, hyperosmolar solutions are used in clinical practice to lower intracranial pressure through the osmotic movement of water from the brain tissue.³⁴ Water accumulation in brain tissue has also been observed due to increased post-trauma osmolarity and in ischemia.^{37, 38} According to this theory, hydrocephalus would be a pathological state rather than pathology in itself and its origin would not lie mainly in an overproduction of CSF in the choroid plexuses, an alteration in its circulation, or an absorption insufficient at the level of the arachnoid villi, but rather the result of various pathophysiological processes that affect them. They would regulate the extracellular volume as in other parts of the body.³⁴

The CPC would be intended to help the hydrodynamic balance of the CSF, but it is difficult to know if the CPC has a long-term effect in reducing the production of CSF and thus helps the dynamic balance of the CSF, or during the time that CPC works, allow the body to increase the CSF reabsorption.^{18, 23-}



Studies in the population with hydrocephalus show variable success rates according to the characteristics of the patients (33.3% - 73.3%) with an overall effectiveness rate of 46.7%. All the studies included in the analysis were retrospective studies, most of them also with small population sizes. Selection bias is high; few studies have a patient selection system to use this procedure. Furthermore, significant losses to follow-up are reported without assigning them as failures. To minimize confounding bias, the statistical significance of different factors was calculated, so that no greater weight was assigned to a specific one or to the association with another.

Pople and Ettles³⁹ describe in their series that in those patients with rapidly progressive hydrocephalus (tense fontanelle) CPC was less effective (11% vs 46%, $p = 0.03$), but this represents an important measurement bias because it represents the evolution of a parameter by means of a subjective clinical estimation at a given time. Shitsama et al.⁴³ describe the same effect ($p = 0.045$), but how this conclusion was reached is not mentioned. The positive results found in this group of patients could in part be due to milder hydrocephalus, with even a possible spontaneous arrest of disease progression independent of the procedure. However, it is not possible to draw a conclusion without



knowing the progression of a certain parameter over time until the time of surgery and establish cut-off points to separate the "slowly" from the "rapidly progressive" one. In *Figure 2*, an original algorithm is proposed to decide to perform a CPC, based on the variables studied in this review.

In a population with communicating hydrocephalus, success rates are higher than in non-communicating hydrocephalus (47.4% vs 11.1%) and like myelomeningocele (45.7%). This may have to do with a pathophysiological explanation since in non-communicating hydrocephalus the main problem would be determined by an obstruction at the level of the subarachnoid space and/or in the ventricular system, so plexus ablation would not have a major role in your resolution. It is for this reason that CPC would not be indicated in obstructive hydrocephalus.

The etiology was significantly associated with the effectiveness of the procedure, the latter being the highest in patients with hydranencephaly or maximum hydrocephalus (68.9%, $p = 0.001276$). It is important not to confuse hydranencephaly or maximum hydrocephalus with extreme hydrocephalus, in the latter group the procedure was successful only in 37.5% of the cases. Hydranencephaly is a condition with high mortality, mostly in the first two years of life, in which the main cause of death is pulmonary complications and infections.⁵⁰ An absent cortex or a remnant of it means that in these patients a CSF shunt has a greater risk of complications, mainly CSF leak, shunt dysfunction, and skin damage due to thinning of the "Scalp".^{19, 20} For this reason, CPC emerges as a management option for this complex type of patients with the aim of reducing complications associated with interventions for the treatment of hydrocephalus, reducing the number of interventions and improving the quality of life of patients.

Even though multiple studies have established that most of the CSF would be produced in the ependyma,⁵¹⁻⁵³ in these patients, in particular, the lack of brain parenchyma as a CSF producer and the greater ease of performing the procedure due to anatomical distortion, mainly absence or thinning of the septum pellucidum for the coagulation of the contralateral plexus, could be the cause of the favorable results. The only prospective study⁴¹ that compared CPC with VPS for the treatment of hydranencephaly showed that there is no significant difference between their success rates. In addition, it showed that the cost associated with VPS is more than double that of a CPC, due to the supplies used, the interventions, and the total number of extra bed days used. In contexts of limited resources, the latter can be decisive when choosing a procedure.

CPC occurs in the treatment of choroid plexus hyperplasia (CPH), a rare pediatric disorder that would always present with increased CSF production.²¹ This increased CSF production would determine a higher risk of complication of a shunt, a review study²¹ showed that 16 of 17 patients with CPH developed ascites associated with VPS. In most cases, the final procedure is a plectomy, but this is a procedure with a high risk of bleeding,²² so CPC appears like a safer option. The evidence is scant, and they are only case reports. The diagnosis is suspected with a bilaterally enlarged choroid plexus on preoperative MRI and is confirmed by histology with normal plexus, without mitotic figures or elevated Ki67. In all cases, CPC is presented as a secondary procedure for the treatment of CPH when VPS has failed. In the only patient in whom CPC was evaluated as a definitive procedure to treat hydrocephalus secondary to HPC, the procedure was successful.²¹ In the other studies found, no attempt was made to leave the patients free of a shunt, therefore, we cannot draw conclusions regarding the

effectiveness of CPC as management of hydrocephalus in this group and were also not included in the results of this review. In these last-mentioned studies, it was found that in 3 patients⁵⁴⁻⁵⁶ CSF production decreased and in 1 case⁵⁷ it remained the same. Considering the quality of the available evidence and the low probability of a prospective study due to the epidemiology of this pathology, CPC may be useful as a definitive treatment for this disorder, and with more security, it may also be useful in reducing the risk of development of ascites when associated with VPS, as well as avoiding the risks associated with a plexectomy.

The degree of CPC is associated with the effectiveness of the procedure, with a higher success rate in those that included coagulation of the choroid plexus of the temporal horns (64.7 vs 43.3%, $p = 0.048068$). This is probably explained by greater control of CSF production in the choroid plexuses; therefore, extensive cauterization of the plexuses is recommended, including both plexuses corresponding to the temporal horns.

The use of a flexible endoscope reported a higher success rate than the rigid endoscope (75% vs 44.7%, $p = 0.0699$). This difference close to statistical significance can be explained by the small sample size in the flexible endoscope group (5.7% of the total sample). The use of a flexible endoscope would be associated with success because it would technically facilitate the coagulation of a greater proportion of the plexus in relation to a rigid endoscope.^{58,59}

The type of approach was also significantly associated with the effectiveness of the procedure ($p = 0.000604$). Maximum effectiveness was achieved through a parietal approach (74.4%), while the other approaches had similar success rates (37.5 - 43.3%). One of the advantages of the parietal approach is that it does not need more than one entry point, unlike the bi-occipital approach in which 2 burr holes are required, which in certain cases it is even mentioned that they were placed with the help of Neuronavigation, a resource not always available.

Like what happened with the almost exclusive use of a rigid endoscope, the monopolar electrode was the choice in 96.2% of the sample. Thus, the type of electrode was not significantly associated with the effectiveness of the procedure ($p = 0.4631$). In the only patient who exclusively used a bipolar electrode, the procedure was successful. With the present results, an assessment of the role of the bipolar electrode in CPC cannot be made, but it is not ruled out that it may be used in centers with experience in its use. In other cases, it is prudent to proceed with a monopolar electrode due to the bulk of published evidence with its use.

The presence of a previous VPS was not significantly associated with a lower CPC effectiveness ($p = 0.3241$). This possibly due to processes in which the overproduction of CSF by the plexus prevailed and that the derivation was not able to balance.

CONCLUSION

Isolated CPC is a viable treatment option for hydranencephaly, choroid plexus hyperplasia, and to a lesser extent for communicating hydrocephalus with non-tense fontanelle. Factors associated with its success are a greater degree of coagulation of the choroid plexus, a parietal approach, and probably the use of a flexible endoscope.

Finally, more prospective evidence is still needed that directly compares CPC with bypass therapies and evaluates long-term functional and neurocognitive outcomes when possible, as well as patient and family satisfaction and quality of life. The latter is of special importance in patients who have a reserved survival prognosis such as hydranencephaly. All this, with the objective to offer the most information to the family when making the decision about a procedure to be carried out.

REFERENCES

- Dandy WE. Extirpation of the choroid plexus of the lateral ventricles in communicating hydrocephalus. *Ann Surg* 1918;68: 569-579.
- Dandy WE. The operative treatment of communicating hydrocephalus. *Ann Surg* 1938;108: 194-202.
- L'Espinasse VL; in Davis (ed): **Neurological Surgery. Philadelphia**, Lea & Febiger, 1943, ed 2, p 442.
- Scarff JE. Evaluation of treatment of hydrocephalus. Results of third ventriculostomy and endoscopic cauterization of choroid plexuses compared with mechanical shunts. *Arch Neurol* 1966; 14:382-391.
- Putnam TJ. Treatment of hydrocephalus by endoscopic coagulation of choroid plexuses: description of new instrument. *N Engl J Med* 1934; 210:1373-1376.
- Davidoff LM. Hydrocephalus and hydrocephalus with meningocele: Their treatment by choroid plexectomy. *Surg Clin North Am* 1948; 28:416-431.
- Sachs E. Hydrocephalus: An analysis of 98 cases. *J Mt Sinai Hosp* 1942; 9:767-791
- Milojević AJ, Radojčić BS, Meljnikov ID. Hydrocephalus – History of surgical treatment over the centuries. *Sanamed* 2012; 7(2): 119-125.
- Wu Y, Green NL, Wrensch MR, et al. Ventriculoperitoneal shunt complications in California: 1990 to 2000. *Neurosurgery*. 2007; 61(3):557-563.
- Warf BC. Comparison of endoscopic third ventriculostomy alone and combined with choroid plexus cauterization in infants younger than 1 year of age: a prospective study in 550 African children. *J Neurosurg* 2005; 103: 475-481.
- Warf B, Ondoma S, Kulkarni A, et al. Neurocognitive outcome, and ventricular volume in children with myelomeningocele treated for hydrocephalus in Uganda. *J Neurosurg Pediatr* 2009;4:564-570.
- Warf BC. Congenital idiopathic hydrocephalus of infancy: the results of treatment by endoscopic third ventriculostomy with or without choroid plexus cauterization and suggestions for how it works. *Childs Nerv Syst* 2013; 29:935-940.
- Warf BC, Campbell JW. Combined endoscopic third ventriculostomy and choroid plexus cauterization as

- primary treatment of hydrocephalus for infants with myelomeningocele: long-term results of a prospective intent-to-treat study in 115 East African infants. *J Neurosurg Pediatr* 2008;2:310-316.
14. Warf BC, Campbell JW, Riddle E. Initial experience with combined endoscopic third ventriculostomy and choroid plexus cauterization for post-hemorrhagic hydrocephalus of prematurity: the importance of preoperative cistern status and the predictive value of FIESTA MRI imaging. *Childs Nerv Syst.* 2011;27(7):1063-1071.
 15. Warf BC, Dewan M, Mugamba J. Management of Dandy-Walker complex-associated infant hydrocephalus by combined endoscopic third ventriculostomy and choroid plexus cauterization. *J Neurosurg Pediatr* 2011;8:377-383.
 16. Warf BC, Stagno V, Mugamba J. Encephalocele in Uganda: ethnic distinctions in lesion location, endoscopic management of hydrocephalus, and survival in 110 consecutive children. *J Neurosurg Pediatr* 2011; 7: 88-93.
 17. Warf BC, Tracy S, Mugamba J. Long-term outcome for endoscopic third ventriculostomy alone or in combination with choroid plexus cauterization for congenital aqueductal stenosis in African infants. *J Neurosurg Pediatr* 2012; 10: 108-111.
 18. Morota N, Fujiyama Y. Endoscopic coagulation of choroid plexus as treatment for hydrocephalus: indication and surgical technique. *Childs Nerv Syst* 2004; 20:816-820.
 19. Wellons JC 3rd, Tubbs RS, Leveque JC, et al. Choroid plectomy reduces neurosurgical intervention in patients with hydranencephaly. *Pediatr Neurosurg.* 2002; 36(3):148-152.
 20. Griffith HB, Jamjoom AB. The treatment of childhood hydrocephalus by choroid plexus coagulation and artificial cerebrospinal fluid perfusion. *Br J Neurosurg.* 1990;4(2):95-100.
 21. Hallaert GG, Vanhauwaert DJ, Logghe K, et al. Endoscopic coagulation of choroid plexus hyperplasia. *J Neurosurg Pediatr.* 2012;9(2):169-177.
 22. Piastra M, Di Rocco C, Tempera A, et al. Massive blood transfusion in choroid plexus tumor surgery: 10-years' experience. *J Clin Anesth* 2007;19:192-197.
 23. Orešković D, Radoš M, Klarica M: Role of choroid plexus in cerebrospinal fluid hydrodynamics. *Neuroscience* 2017; 354:69-87.
 24. Bering EA Jr. Circulation of the cerebrospinal fluid. Demonstration of the choroid plexuses as the generator of the force for flow of fluid and ventricular enlargement. *J Neurosurg* 1962; 19:405-413.
 25. Egnor M, Zheng L, Rosiello A, et al. A model of pulsations in communicating hydrocephalus. *Pediatr Neurosurg* 2002; 36:281-303.
 26. Wilson CB, Bertan V. Interruption of the anterior choroidal artery in experimental hydrocephalus. *Arch Neurol* 1967; 17:614-619.
 27. Di Rocco C, Pettorossi VE, Caldarelli M, et al. Communicating hydrocephalus induced by mechanically increased amplitude of the intraventricular cerebrospinal fluid pressure: experimental studies. *Exp Neurol* 1978; 59:40-52.
 28. Karimy JK, Duran D, Hu JK, et al. Cerebrospinal fluid hypersecretion in pediatric hydrocephalus. *Neurosurg Focus.* 2016;41(5): E10.
 29. Grunert P, Charalampaki P, Hopf N, Filippi R. The role of third ventriculostomy in the management of obstructive hydrocephalus. *Minim Invasive Neurosurg* 2003; 46:16-21.
 30. Javadpour M, Mallucci C. The role of neuroendoscopy in the management of tectal gliomas. *Childs Nerv Syst.* 2004;20(11-12):852-857.
 31. Teo C, Jones R. Management of hydrocephalus by endoscopic third ventriculostomy in patients with myelomeningocele. *Pediatr Neurosurg.* 1996;25(2):57-63.
 32. Oi S, Di Rocco C. Proposal of "evolution theory in cerebro-spinal fluid dynamics" and minor pathway hydrocephalus in developing immature brain. *Childs Nerv Syst* 2006; 22:662-669.
 33. Zandian A, Haffner M, Johnson J, et al. Endoscopic third ventriculostomy with/without choroid plexus cauterization for hydrocephalus due to hemorrhage, infection, Dandy-Walker malformation, and neural tube defect: a meta-analysis. *Childs Nerv Syst.* 2014;30(4):571-578.
 34. Orešković D, Klarica M. Development of hydrocephalus and classical hypothesis of cerebrospinal fluid hydrodynamics: facts and illusions. *Prog Neurobiol.* 2011;94(3):238-258.
 35. Go KG. The normal and pathological physiology of brain water. *Adv. Tech. Stand. Neurosurg.* 1997; 23:47-142.
 36. Verbalis JG. Brain volume regulation in response to changes in osmolality. *Neuroscience.* 2010;168(4):862-870.
 37. Hossmann KA. The pathophysiology of ischemic brain swelling. 1985, In: Inaba, Y., Klatzo, I., Spatz, M. (Eds.), *Brain Edema. Springer-Verlag*, Berlin, Heidelberg, New York, Tokyo, pp. 365-384.
 38. Kawamata T, Mori T, Sato S, Katayama Y. Tissue hyperosmolality and brain edema in cerebral contusion. *Neurosurg Focus.* 2007;22(5): E5.
 39. Pople IK, Ettles D. The role of endoscopic choroid plexus coagulation in the management of hydrocephalus. *Neurosurgery* 1995;36(4):698-702.
 40. Okano A, Ogiwara H. Long-term follow-up for patients with infantile hydrocephalus treated by choroid plexus coagulation. *J Neurosurg Pediatr* 2018; 22(6):638-645.
 41. Ogiwara H, Uematsu K, Morota N. Obliteration of the choroid plexus after endoscopic coagulation. *J Neurosurg Pediatr.* 2014;14(3):230-233.
 42. Pedrosa HA, Lemos SP, Vieira C, et al. Choroid plexus cauterization on treatment of hydranencephaly and maximal hydrocephalus. *Childs Nerv Syst.* 2017;33(9):1509-1516.
 43. Shitsama S, Wittayanakorn N, Okechi H, Albright L. Choroid plexus coagulation in infants with extreme hydrocephalus or hydranencephaly. *J Neurosurg Pediatr* 14:55-57, 2014.
 44. Sandberg DI, Chamiraju P, Zoeller G, et al. Endoscopic choroid plexus coagulation in infants with hydranencephaly or hydrocephalus with a minimal cortical mantle. *Pediatr Neurosurg* 2012;48(1):6-12.
 45. Gomes FL, Loduca RD, Homa MN, Collange NZ. Endoscopic coagulation of choroid plexus in three children with severely advanced forms of hydrocephalus. *J Neurol Surg A Cent Eur Neurosurg* 2015; 76 (1): 25-29.
 46. Kim SY, Cho JH, Kim KH. Endoscopic Coagulation of Choroid Plexus in Hydranencephaly. *J Korean Neurosurg Soc* 2014;55(6):375-378.
 47. Ray C, Mobley J, Thompson M, Nagy L. Hydranencephaly: Considering Prolonged Survival and Treatment by Endoscopic Choroid Plexus Coagulation. *Turk Neurosurg.* 2015;25(5):788-792.
 48. Malheiros JA, Trivelato FP, Oliveira MM, et al. Endoscopic choroid plexus cauterization versus ventriculoperitoneal shunt for hydranencephaly and near hydranencephaly: a prospective study. *Neurosurgery* 2010; 66:459-464; discussion 464.
 49. Laurence KM, Coates S. The natural history of hydrocephalus. Detailed analysis of 182 unoperated cases. *Arch Dis Child.* 1962;37(194):345-362.
 50. Merker B. Life expectancy in hydranencephaly. *Clin Neurol Neurosurg* 2008;110(3):213-214.
 51. Milhorat TH, Hammock MK, Chien T, Davis DA. Normal rate of cerebrospinal fluid formation five years after bilateral choroid plectomy. Case report. *J Neurosurg.* 1976;44(6):735-739.

52. Pollay M, Curl F. Secretion of cerebrospinal fluid by the ventricular ependyma of the rabbit. *Am J Physiol.* **1967**;213(4):1031-1038.
53. Sato O, Bering EA. Extra-ventricular formation of cerebrospinal fluid. *No To Shinkei.* **1967**;19(9): 883-885.
54. Tamburrini G, Caldarelli M, Di Rocco F, et al: The role of endoscopic choroid plexus coagulation in the surgical management of bilateral choroid plexuses hyperplasia. *Childs Nerv Syst* **2006**; 22:605–608.
55. Philips MF, Shanno G, Duhaime AC. Treatment of villous hypertrophy of the choroid plexus by endoscopic contact coagulation. *Pediatr Neurosurg* **1998**; 28:252–256.
56. Bucholz RD, Pittman T. Endoscopic coagulation of the choroid plexus using the Nd:YAG laser: initial experience and proposal for management. *Neurosurgery* **1991**; 28:421–427.
57. Kasper J, Krause M, Siekmeyer M, Gräfe D, Meixensberger J, Wilhelmy F. Choroid plexus coagulation in trisomy 9 mosaic-related hydrocephalus-a case report [published online ahead of print, 2020 May 8]. *Childs Nerv Syst.* **2020**;10.1007/s00381-020-04643-1.

Disclosures

The authors report no conflict of interest concerning the materials or methods used in this study or the findings specified in this paper.

Authors Contributions

Conception and design: Smoquina, Zulueta. *Drafting the article:* Smoquina. *Critically revising the article:* Smoquina. *Reviewed submitted version of manuscript:* Smoquina, Zulueta. *Approved the final version of the manuscript on behalf of all authors:* Smoquina.

Correspondence

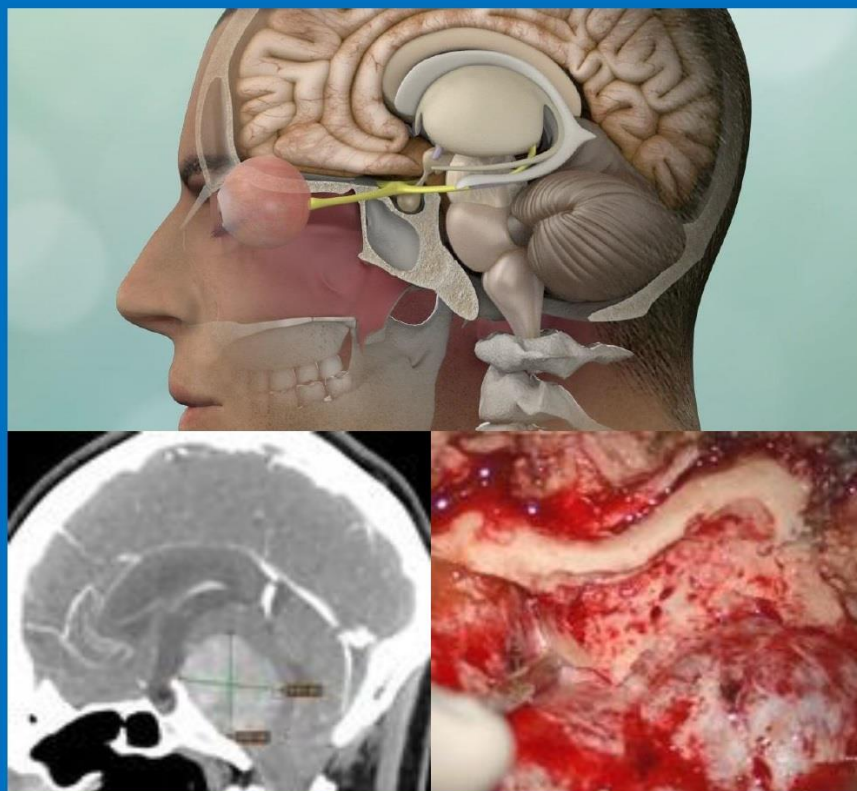
Stefano Smoquina. *Neurosurgery Fellow. University of Valparaíso, Chile. E-mail:* stefano.smoquina@gmail.com

NEXT ISSUE

PJNS PERUVIAN JOURNAL OF **NEUROSURGERY**

Vol 3 | Issue 3 | Jul-Sep 2021

CRANIAL BASE SURGERY



Transpetrosal Approach, Minipterional Approach